

We Will Not Be De-*feet*-ed

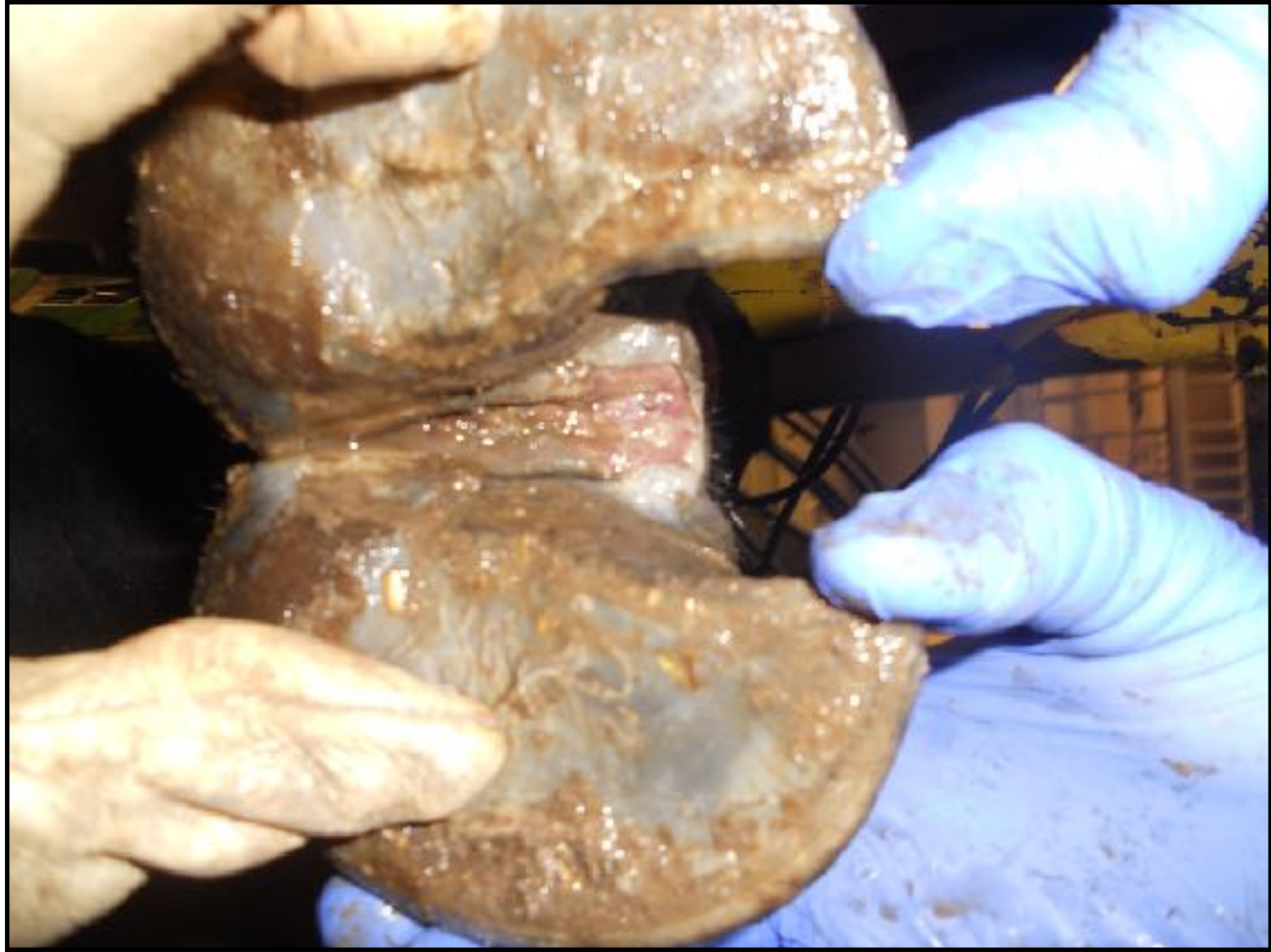Meredyth Jones DVM, MS, DACVIM

Oklahoma State University College of Veterinary Medicine

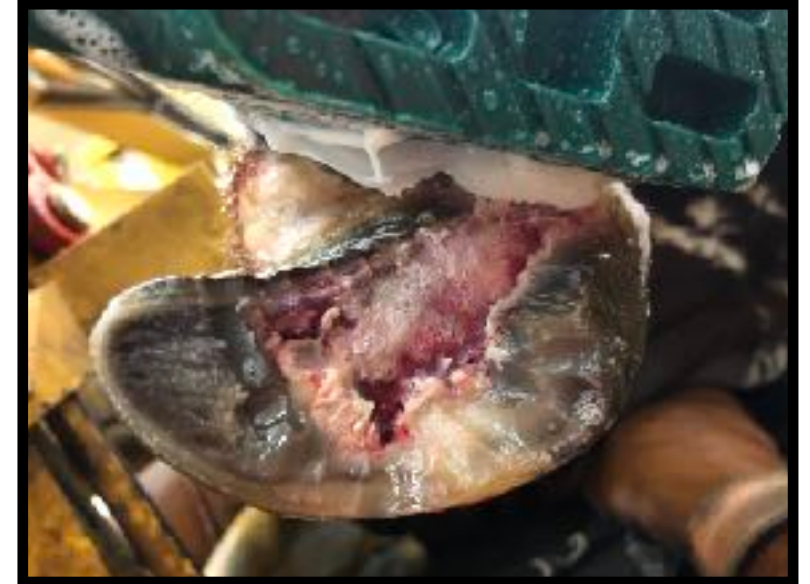
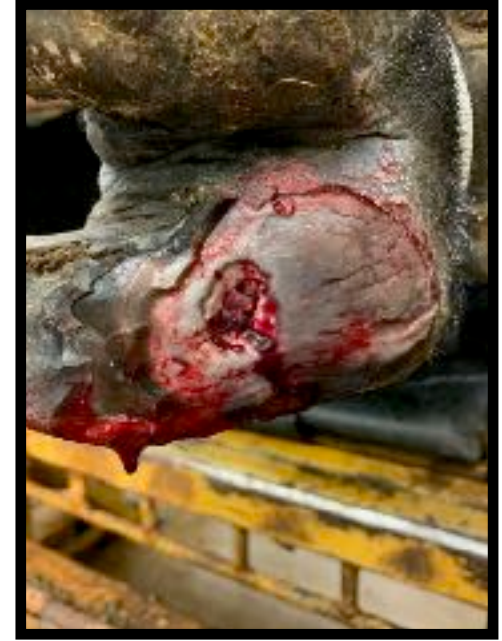
Today's Topics

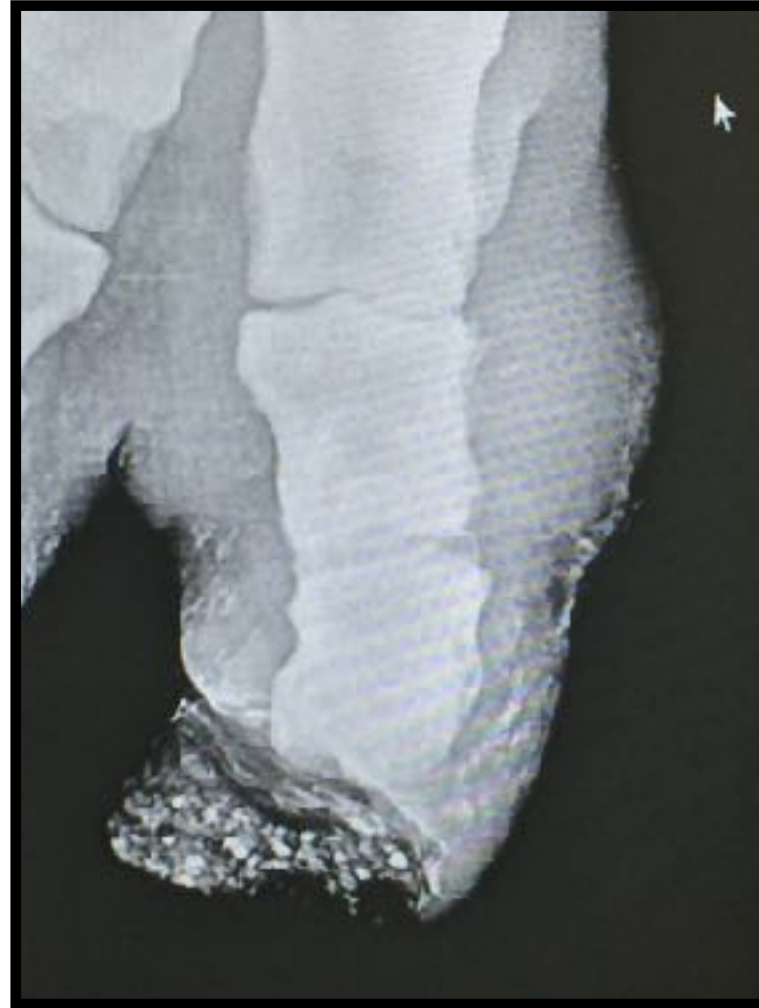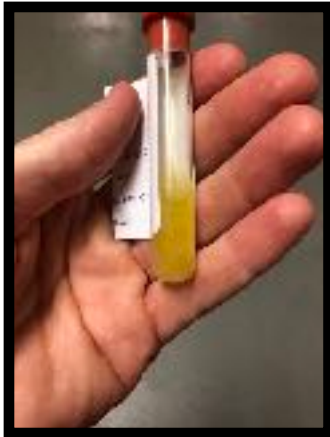- Is it footrot?
- Deep digital infection
- Regional antibiotic treatments
- Current research
- Corns
- Corkscrew Claw
- Fractures



Footrot?



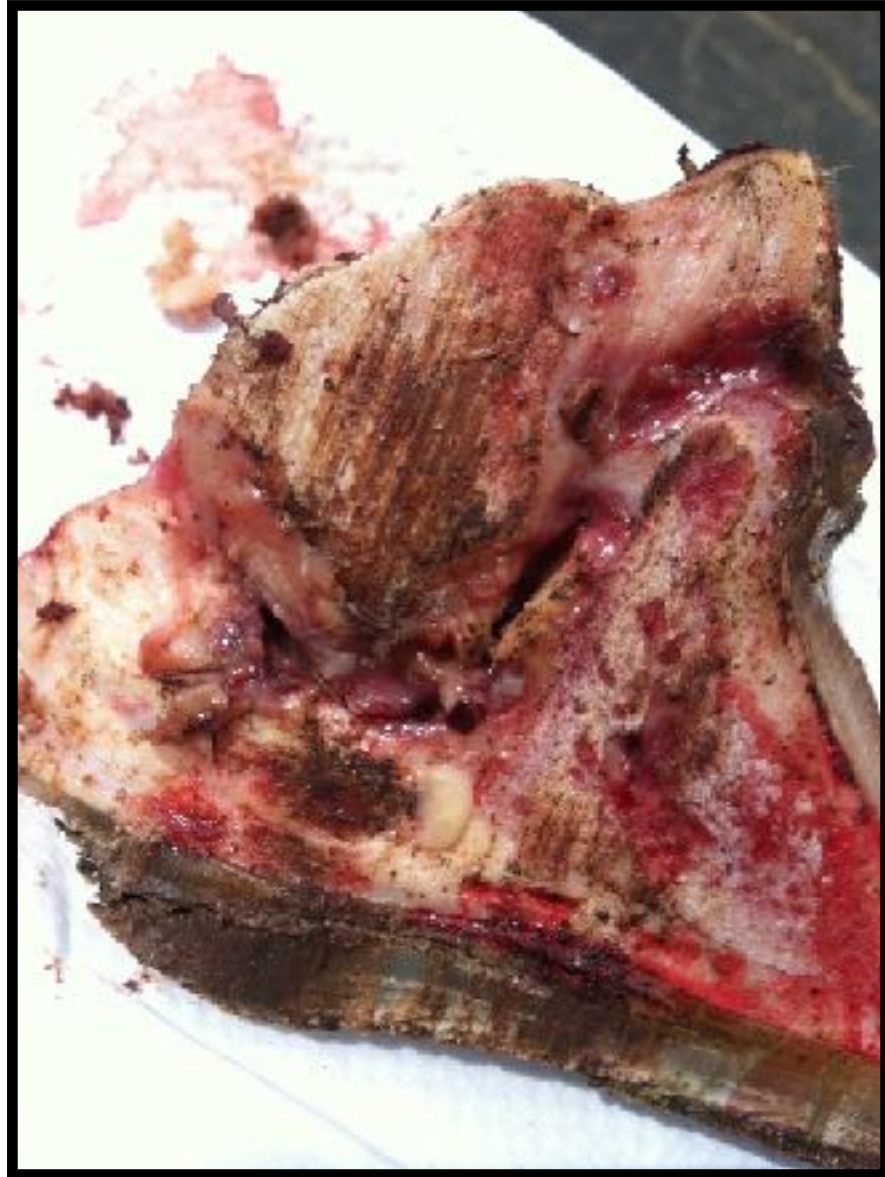Deep Digital Sepsis



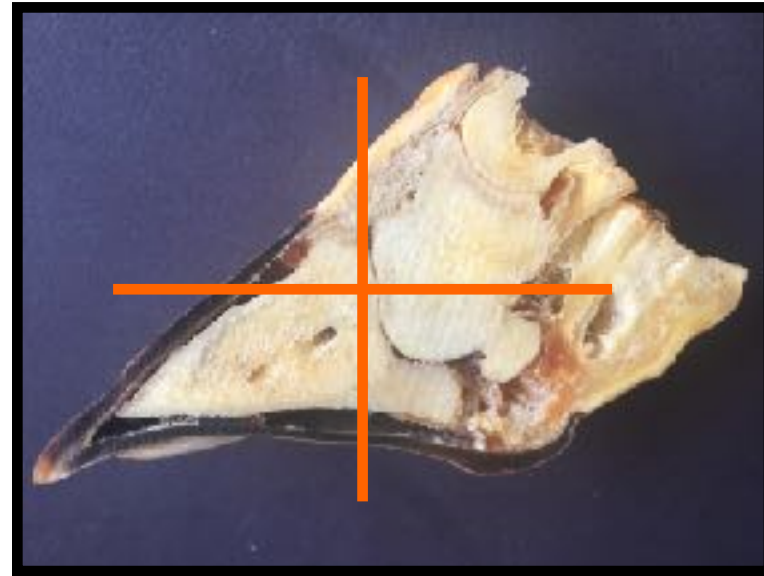
Claw Amputation

- Rapid pain relief
- Meet a production goal
- Longevity
 - > 680kg short production life [Pejsa et al 1993]
 - Bulls 27.2 months [Starke 2006]
 - Dairy cows 13.5 months [Starke et al 2007]





Claw-Sparing



Regional Intravenous Limb Perfusion



Regional Intravenous Limb Perfusions

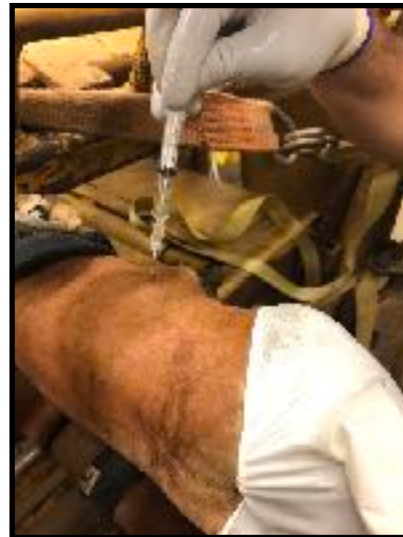- Antimicrobial
 - No labelled products
 - PK data
 - Ampicillin-sulbactam [Depenbrock et al 2017]
 - ~~×~~ Cefazolin [Gagnon et al 1994]
 - ~~×~~ Ceftiofur sodium [Navarre et al 1999]
 - Florfenicol [Gilliam et al 2008]
 - ~~×~~ Tetracycline HCl [Rodrigues et al 2010]
 - ~~×~~ Marbofloxacin [Celani et al 2017]



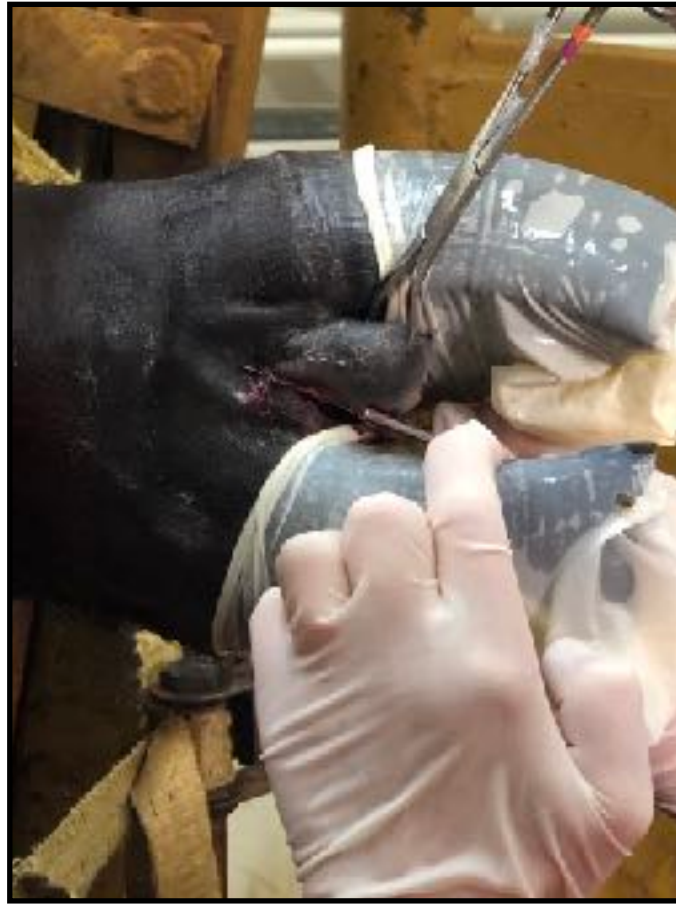
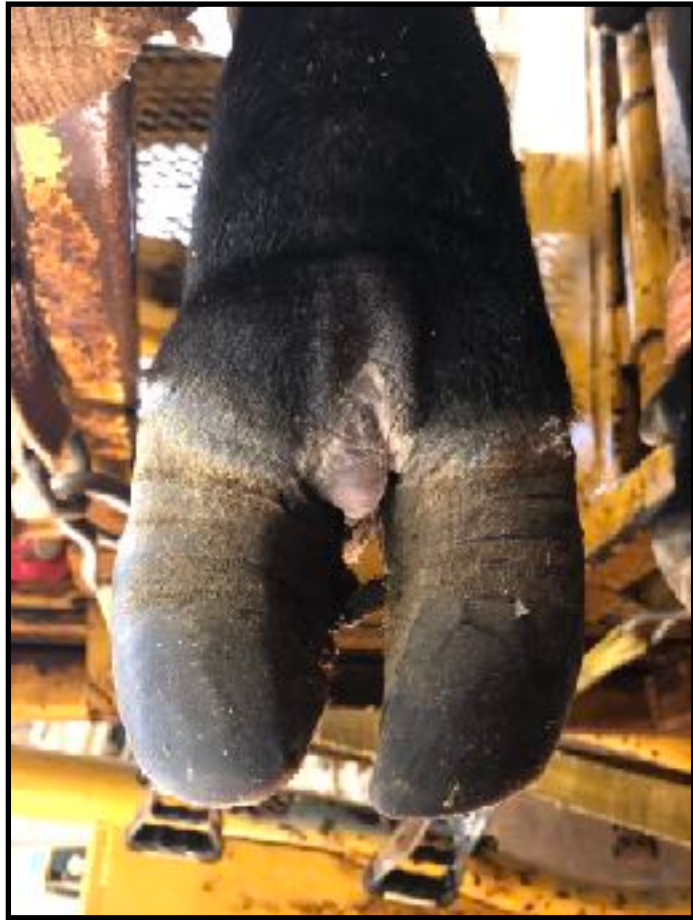Current Research



- With only 2 legal and available drugs for use in the foot, we are evaluating alternatives
- We have set out to establish the distribution of other antimicrobials that may be more user-friendly and effective



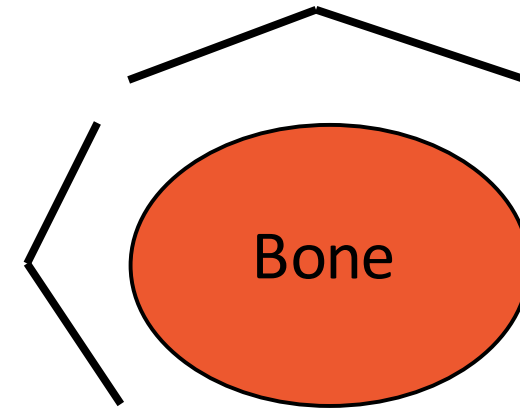
Corns



Corkscrew Claw



Fractures



What to know when you call


Front leg or back leg

Mild pain, won't bear weight, won't put down

Swelling above or below knee (carpus) or hock

Bone sticking out

Bleeding





Meredyth Jones DVM, MS, DACVIM

405-744-7000